

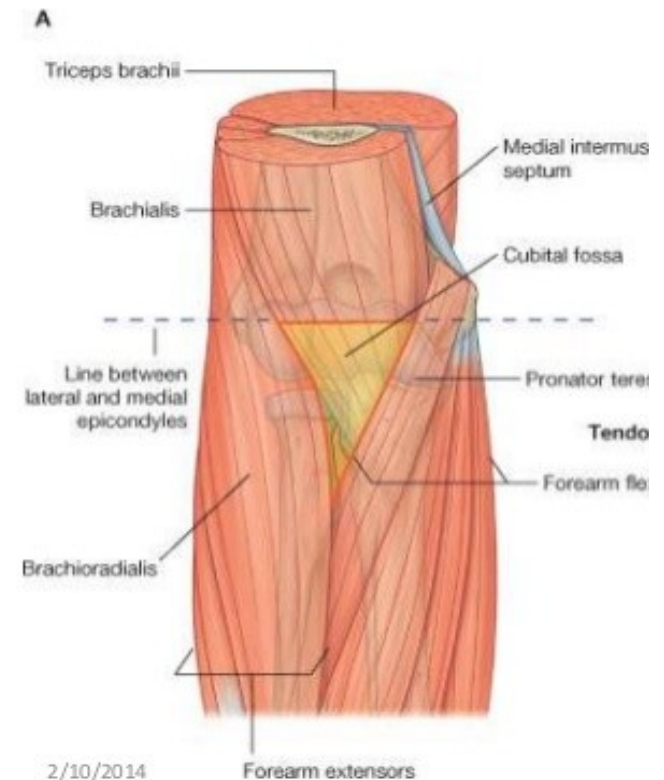


# ***CUBITAL FOSSA***

Dr. A. Thamarai Selvi  
Assistant Professor  
Department of Anatomy  
KIMS

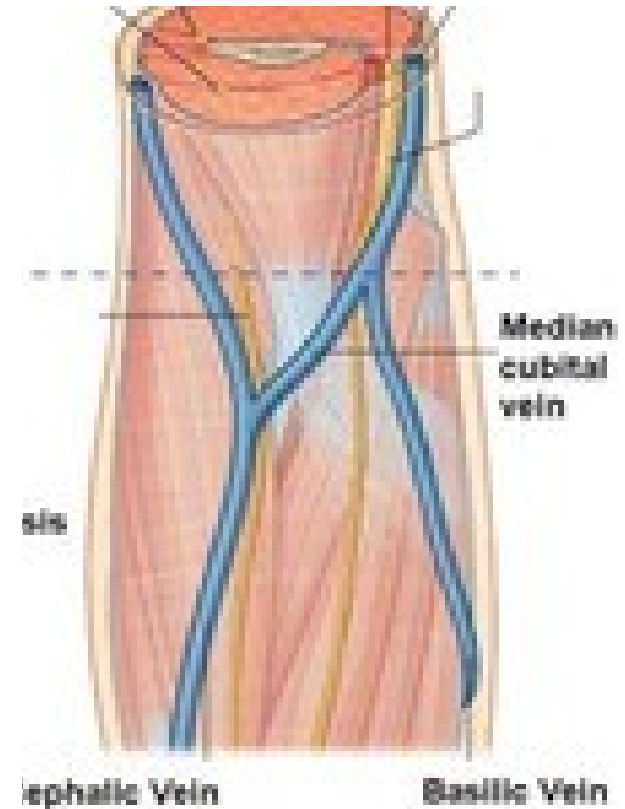
# INTRODUCTION

- Cubitus- elbow region
- Fossa- hollowness
- Triangular shaped fossa
  - 3 borders and a apex
  - Has roof and floor
- Located on the anterior aspect of elbow



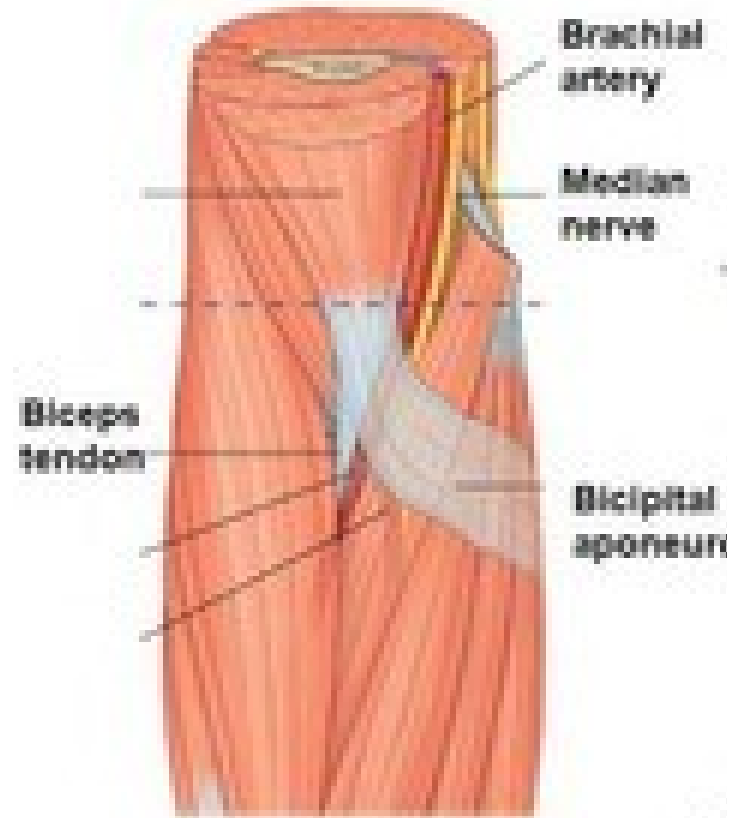
# ROOF & FLOOR

- **ROOF:**
  - From superficial to deep
    - ▣ Skin
    - ▣ Superficial fascia (median cubital vein and cutaneous nerves)
    - ▣ Deep fascia (reinforced by bicipital aponeurosis)
- **FLOOR:**
  - By Brachialis and Supinator muscles



# BOUNDARIES

- Lateral-  
Brachioradialis  
muscle
- Medial- Pronator  
Teres muscle
- Base (superior)-  
imaginary line joining  
two epicondyles of  
Humerus
- Apex- meeting point  
of lateral and medial  
borders



# CONTENTS

- From medial to lateral
  - Median nerve
  - Brachial artery
  - Biceps brachii tendon
  - Superficial branch of Radial nerve

# APPLIED ANATOMY

- Median cubital vein- for intravenous injections and collecting blood samples
- Brachial artery- Brachial pulse and BP measurement
- Supracondylar fracture of Humerus- Volkmann's ischemic contracture

